



Anitua, Eduardo
MD, DDS, PhD, Eduardo Anitua
Foundation, Vitoria, Spain.



Original article

Atraumatic extraction of implants: predictability of the technique and the re-implanted implant

Published in Spanish *Científica Dental* Vol. 13. Nº 3. 2016
www.cientificadental.es

ABSTRACT

Introduction: Reversibility of implant treatment is currently one of the key points for retreatment in cases in which there has been peri-implantitis or bone loss that leads to implant failure. A technique that allows for atraumatic extraction of the implant and reinsertion in the same surgical phase effectively resolves the problem.

Methods: This is a pilot study on nine patients who underwent implant removal and implantation in the same surgical phase and location. These reinserted implants were monitored over time to evaluate survival.

Results: Implants were monitored for 50 ± 2 months from insertion (range 48-52 months) and 43 ± 3 months from loading (range 40 to 48 months). No failed implant was observed during follow-up. Mesial bone loss was 1.0 ± 0.8 mm and distal bone loss was 1.0 ± 0.8 mm.

Conclusions: The atraumatic removal technique is safe and predictable and can be used without risk in the majority of implants currently on the market.

KEYWORDS

Implant removal; Peri-implantitis;
Reimplanted implant

Indexed in:

- IME
- IBECs
- LATINDEX
- GOOGLE SCHOLAR

Correspondence address:

Dr. Eduardo Anitua
C/ José María Cagigal, 19.
10005 Vitoria, Spain
+34 945160653

Date received: 18 September 2016.
Date accepted for publication: 4 November 2016

INTRODUCTION

Removal of failed implants for various reasons is a growing challenge in our practice. In order to solve this new problem, different techniques have been developed other than complete trephining and removal of the implant with surrounding bone cylinder, which are considered the traditional techniques.

Several studies on the implant removal techniques can be found in the international literature. The study by Covani *et al.* in 2006 and 2009^{1,2} shows a more conservative technique than conventional trephines for the removal of implants using a low-revolution drill with irrigation that is capable of removing the bone around the implant. When the bone is removed, the structural union is broken from the integration and the implant can be removed. This technique, besides being more conservative than conventional trephining, leaves defects of greater diameter than the extracted implant, resulting in loss of part of the bone bed.

Counter-torque-based techniques have been reported in humans, to remove small-diameter implants, as in the study by Simon *et al.*³ These authors use a device to remove the implants without the intermediate extractor piece. Despite being implants of smaller diameter, they found various negative effects such as: fracture, deformation of the implant and fracture of bone fragments.

The technique reported by our study group (Anitua *et al.*)⁴ allows for atraumatic counter-torque removal of the implant, leaving a completely preserved bone bed. The extractors remove the implant without damaging the area where it was placed and, usually it allows for the insertion of a new implant in the same place during the same surgical act.

In addition, follow-up of these implants inserted in the area of the previous removal is not well documented. There are many studies that report cases of implants placed immediately following extraction, but only a few describes follow-up of implants placed in the same site of tooth removal performed in the same surgical procedure.

MATERIALS AND METHODS

Implant removals were carried out using the explantation kit (BTI Biotechnology Institute, Vitoria, Spain). The kit consists of a wrench that is used to transmit the counter-torque force to the implant through a connector (extractor) that is inserted in the implant's connection. The wrench is set to 200 Ncm so that it disarms automatically when it reaches this level of force, thereby avoiding lesions caused by shearing or bone rupture caused by levels of force greater than 200 Ncm,

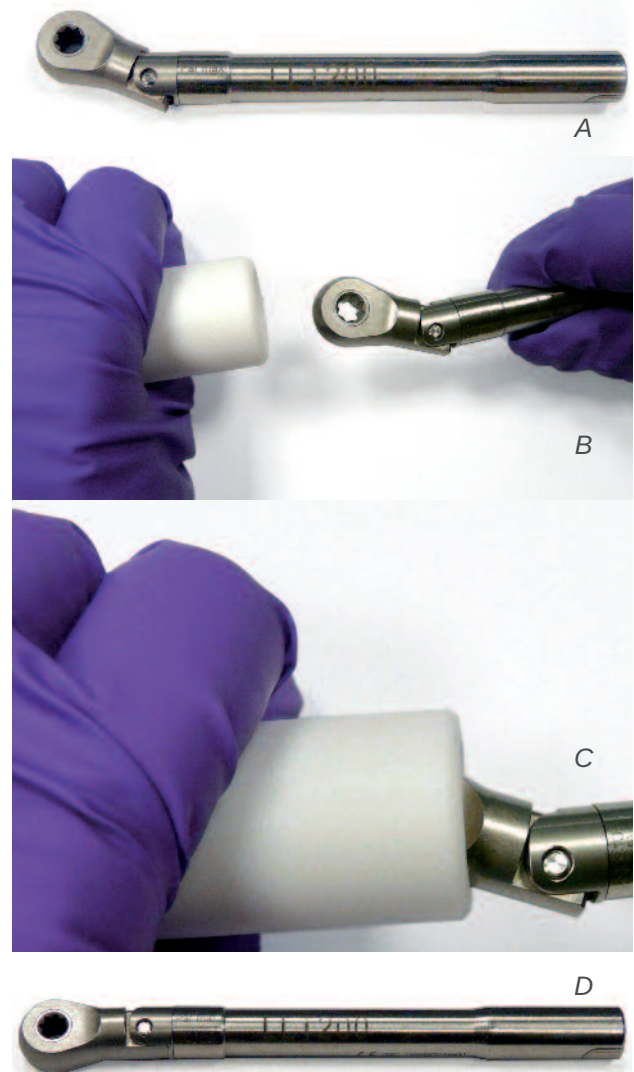


Figure 1.
 A) Wrench that has deactivated upon reaching 200 Ncm.
 B) In order to bypass the deactivation and be able to use it, we introduce the plastic reaming tube.
 C) We apply pressure to move the wrench to its original position (armed).
 D) We remove the wrench from the plastic tube.

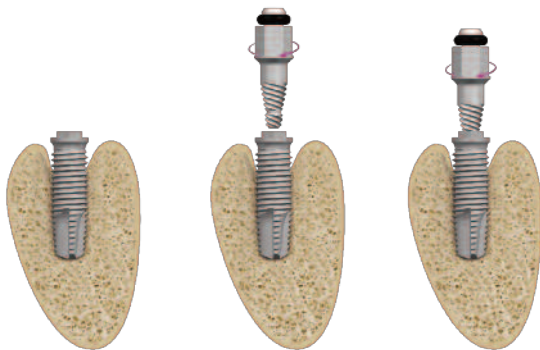


Figure 2. Introduction of the extractor in a counterclockwise direction in the implant connection.

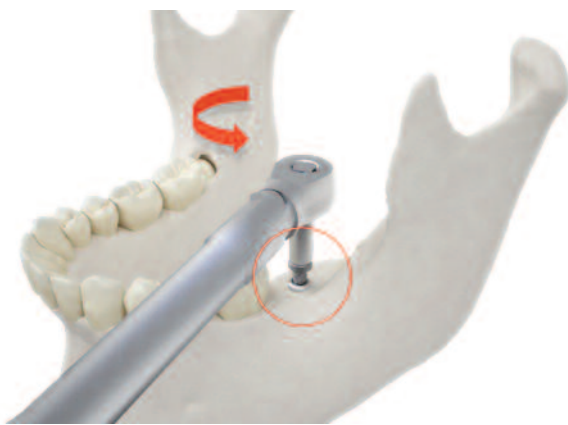


Figure 3. We continue the counterclockwise movement with the torque wrench. It is important that this movement is kept axial to the implant at all times.

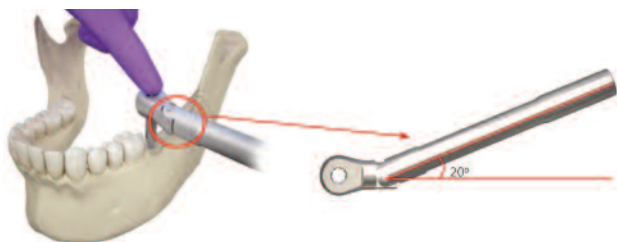


Figure 4. Disarticulation of the torque wrench which indicates that we have reached 200 Ncm.

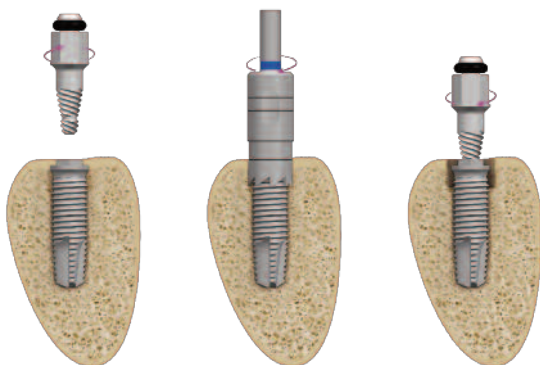


Figure 5. Trephining of the first 2-3 mm of the implant to break the cortical union of the first threads and then an attempt to remove the implant with the extractor.

or fracture of the extractor in the interior of the implant. When the wrench is disarmed, it can be rearmed by applying a counter force in a plastic cylinder that allows for its introduction and righting⁷ (Figure 1).

The extractor is positioned using a manual socket wrench in a counterclockwise direction and then with the anticlockwise force is applied with the wrench (counter-torque) to the implant-extractor set which will cause rupture of the bone-implant union, resulting in loss of osseointegration (Figures 2 and 3).

For cases exceeding 200 Ncm (the removal torque) allowed by the wrench, thereby making it impossible to continue with the removal, ultrafine trephining is performed around the implant (1-2 mm) in the most coronal bone. The maneuver is then attempted again with a new extractor. Elimination of these first millimeters of cortical bone drastically reduces the removal torque and, therefore, we are now able to remove the implant with a counter-torque of less than 200 ncm⁷ (Figures 4 and 5).

Once the new implants were inserted, they were monitored in order to evaluate the predictability of the reimplanted implant.

RESULTS

Nine removals were carried out in nine patients in which new implants were placed in the same bed and surgical act.

Six of the patients were women with a mean age of 61±4 years. Six of the implants were inserted in the superior maxillary and three in the mandible. The mean extraction torque for the failed implants was 162±41 Ncm.

The implants inserted in the post-removal beds had a mean torque of 36±16 Ncm. Only two implants were inserted with a torque of less than 15 Ncm.

Two implants were short (5.5 mm x 5.5 mm and 5.5 mm x 7.5 mm). Three of the implants were 8.5 mm in length with diameters of 4, 4.5 and 5.5 mm. The remaining implants were 10 to 13 mm in length and 3.75 to 5 mm in diameter.

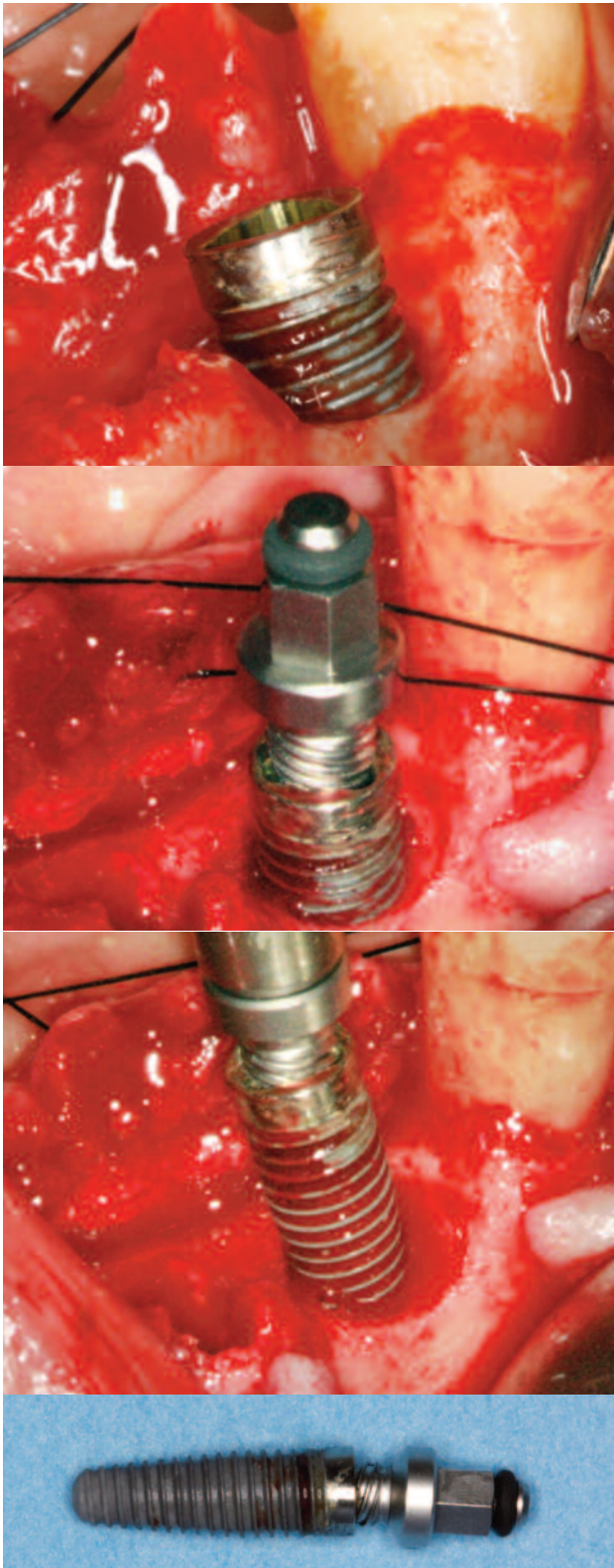


Figure 6. Initial images of the case where the situation of the implant in position 34 can be observed.

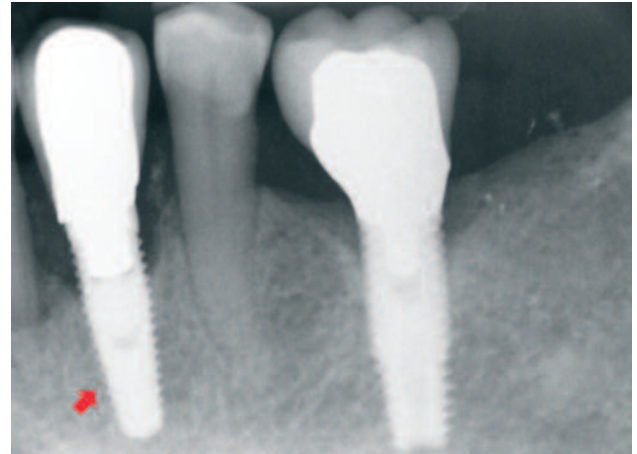


Figure 7. Initial radiograph. We can observe the poor periodontal situation of the antero-interior face. In addition to removal of the implant in position 34, we decided to extract the affected teeth and place implants in the area.

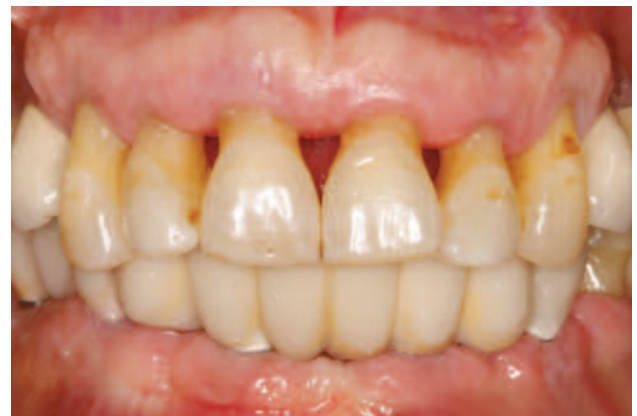

Figure 8. Image of the patient with definitive prosthesis. We can observe the state of the peri-implant and periodontal tissues.

Implants were monitored for 50 ± 2 months from insertion (range 48-52 months) and 43 ± 3 months from loading (range 40 to 48 months). No failed implant was observed during follow-up.

Mesial bone loss was 1.0 ± 0.8 mm and distal bone loss was 1.0 ± 0.8 mm.

DISCUSSION

Many studies report cases of implants placed immediately following extraction, but only a few describe the follow-up of implants placed in the same site of tooth removal performed in the same surgical act.

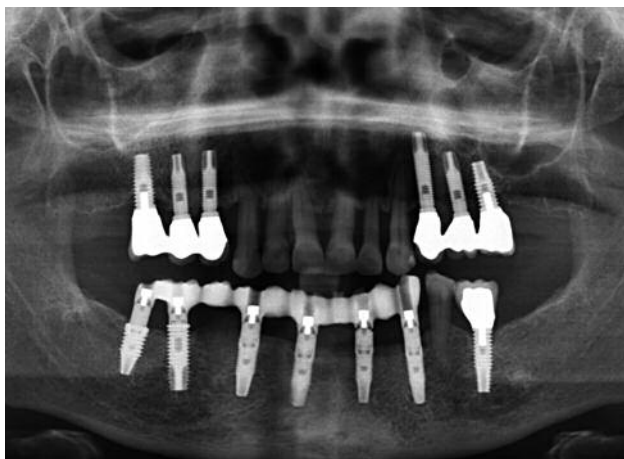

Figure 9. Radiographic image of the definitive prosthetic at one year. We can see the stability of all of the implants placed.

The first studies on the possibility of dental reimplantation after removal in humans and follow-up of the reimplanted implant were by Covani *et al.* (2006, 2009 and 2010).^{1,2,8} In these studies, removal was performed preserving the maximum amount of alveolar bone in the peri-implant bed through the separation of bone that was in contact with the implant by drilling with a fine low speed drill with irrigation. The implants were then placed after another drilling according to the manufacturer's technical specifications with a new drilling to prepare a new slightly wider bed in order to be able to stabilize the implant. All of the implants treated with this method were implants that were removed by fracture at different levels as they were cylindrical threaded implants.

The total number of cases recorded is 9 implants in 9 patients. All of these were rehabilitated after an osseointegration period and there was no sign of early failure at the reentry site. Following prosthetic rehabilitation, all implants were followed for 6 months (12 months in total from the time of insertion), revealing no failure of any of the implants or bone loss greater than that described after normal loading.

The second reference found in the literature was published by Grossmann *et al.* in 2007.⁹ In this study, follow-up was carried out on 31 implants re-implanted in the area of explantation of a previous implant, placed in 28 patients. The mean follow-up was 19.4 months

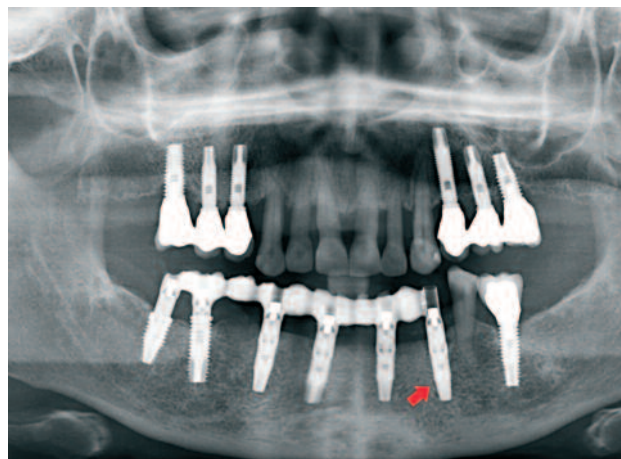


Figure 10. Radiographic image at 3 years. Stability of tissues is maintained.

from placement with a range of between 6 and 46 months. During the follow-up period, nine of the re-implanted implants failed, making the survival rate of 71%, lower than the survival rate for implants placed conventionally. All failures occurred within the first year after placement.

In our study, none of the implants placed in areas where there was previous peri-implantitis had failed. Therefore, immediate insertion of a new implant for the treatment of failed implants may be an alternative to reduce costs, time and surgical morbidity. The atraumatic removal technique is safe and predictable and can be used without risk in the majority of implants currently on the market.

Figures 6 to 10 show surgical images and radiographs of a treated patient in which removals and placements were made in areas of implant extractions.

CONCLUSIONS

The atraumatic removal technique is safe and predictable and can be used without risk in the majority of implants currently on the market.

Insertion of the implants in the same surgical act and bed must be taken into consideration and analyzed together with other factors specific to the receiving bed and the patient, in order to achieve success rates similar to those of implants placed in a primary bed with no previous treatment.



BIBLIOGRAPHY

1. Covani U, Barone A, Cornelini R, Crespi R. Clinical Outcome of implants placed immediately after implant removal. *J Periodontol* 2006;4:722-7.
2. Covani U, Marconcini S, Crespi R, Barone A. Immediate implant placement after removal of failed implant: a clinical and histological case report. *J Oral Implanto!* 2009;4:189-95.
3. Simon H, Caputo AA. Removal torque of immediately loaded transitional endosseous implants in human subjects. *Int J Oral Maxillofac Implants* 2002;17:839-45.
4. Anitua E, Orive G. A new approach for atraumatic implant explanation and immediate implant installation. *Oral Surg Oral Med Oral Pathol Oral Radiol* 2012;113:e19-e25.
5. Anitua E, Alkhraisat MH, Tejero R. Immediate replacement of failed dental implants owing to periimplantitis. *J Oral Science and Rehabil* 2015;1:8-14.
6. Anitua E, Piñas L, Begoña L, Alkhraisat MH. Prognosis of dental implants immediately placed in sockets affected by periimplantitis: A retrospective pilot study. *Int J Periodontics Restorative Dent*. Date accepted: 2014-12-25.
7. Anitua E, Murias-Freijo A, Alkhraisat MH. Conservative implant removal for the analysis of the cause, removal torque and surface treatments of failed nonmobile dental implants. *J Oral Implantol* 2016;42(1):69-77.
8. Covani U, Marconcini S, Santini S, Cornelini R, Barone A. Immediate restoration of single implants placed immediately after implant removal. A case report. *Int J Periodontics Restorative Dent* 2010;30(6):639-45.
9. Grossmann Y, Levin L. Success and survival of single dental implants placed in sites of previously failed implants. *J Periodontol* 2007;78:1670-1674.