



Update

Osteogenesis imperfecta: oral and medical disorders in children

Published in Spanish Científica Dental Vol. 10. Nº 3. 2013.

Jorge Carballido Fernández

Graduate in Dentistry from Complutense University of Madrid.

Marta Monteserín

Matesanz

Graduate in Dentistry from Complutense University of Madrid.

M^a Rosa Mourelle Martínez

Contracted Professor, Doctor of Paediatric Dentistry, Complutense University of Madrid.

Manuel Joaquín de Nova García

Senior Professor of Paediatric Dentistry, Complutense University of Madrid.

Indexed in:

- IME
- IBECs
- LATINDEX
- GOOGLE SCHOLAR

Correspondence address:

Jorge Carballido Fernández
C/Doctor Santero, 7, 1^ªA
28039 Madrid
jcarballido@estumail.ucm.es
jorgecarballidovillablino@gmail.com
Tel.: 696 821 837

Received: 12 July 2013.
Accepted (or accepted for publication):
4 October 2013.

ABSTRACT

Introduction: Osteogenesis imperfecta, also called the brittle bone disease, is a condition characterised by a disorder in the connective tissues of the entire body, including the teeth. The objective of the study was to evaluate the presence of fractures and the bones affected, the presence of dentinogenesis imperfecta, the treatment of osteogenesis imperfecta and the type of bisphosphonate administered.

Method: The clinical histories of 17 patients with osteogenesis imperfecta were evaluated.

Results: Of the patients, 81% suffered fractures, 24% in the femur, 53% of the patients presented dentinogenesis imperfecta, 71% of the patients are treated with bisphosphonates and 83% with pamidronate.

Conclusions: The majority of the patients have suffered fractures during their lives, dentinogenesis imperfecta is frequent in these patients and the majority of them are under treatment with bisphosphonates.

KEYWORDS

Osteogenesis imperfecta; Dentinogenesis imperfecta; Bisphosphonates; Fractures.

INTRODUCTION

Osteogenesis imperfecta (OI) is a hereditary disorder known as the “brittle bone disease”. Its incidence is from 6 to 20 for every 100,000 new births.

It is characterised by presenting a disorder in the connective tissues (developed from the mesenchymal cells that are differentiated in osteoblasts, chondroblasts and fibroblasts during the embryonic stage) of the entire body, including dentition.

Collagen is the most common protein of the body and forms part of the connective tissues present in the bones, in the cartilage and in the blood vessels. There are 19 types of collagen, the most common being type I collagen, which is responsible for providing mechanical resistance to the body structures. The disease is the result of mutations in the genes COL-1A and COL-1B which encode type I collagen¹.

The manifestations that the patients suffer can be grouped into skeletal and non-skeletal. Within the first are found mainly bone fragility and the reduction of the mineral bone mass, which condition the occurrence of fractures. The non-skeletal include the bluish colour of the sclera (Figure 1), dentinogenesis imperfecta, ligamentous hyperlaxity and the presence of wormian bones in the sutures of the cranium².

In 1979, Sillence et al.³ proposed a classification of the disease in four types:

- **Type I:** mild, non-deforming. It is an autosomal dominant entity. The subjects belonging to this group are characterised by having blue sclera, scoliosis (without having major deformities at the level of the spine or long bones) and may present dentinogenesis imperfecta. The principal problem of these individuals is their auditory disability, which may be presented before 20 years of age.
- **Type II:** perinatal lethal. It is autosomal recessive. It is the most severe variety, in which neonatal fractures are produced, the ribs present a beaded radiological image and the long bones seem to have been axially pressed.

- **Type III:** severely deforming. It is autosomal recessive. The subjects pertaining to this entity are characterised by having normal sclera and severe deformities of the spine during the last stage of childhood and adolescence, which bring about low stature. Dentinogenesis imperfecta is frequently present and it especially affects primary dentition. The auditory involvement is quite infrequent.

- **Type IV:** moderately deforming. It is autosomal dominant. It is characterised by grouping the majority of subjects that had been historically diagnosed of the Lobstein’s disease. The sclera is normal.

The Types I, III and IV may present in congenital or late form. Type II is always congenital.

Glorieux et al.⁴ observed that, on occasions, after a fracture or corrective surgery, a hard and painful inflammatory condition may appear, called hyperplastic callus. The authors, in the year 2000, named these cases as Type V OI.

Dentinogenesis imperfecta (DI) deals with a genetic disorder in the formation of the dentin, which involves both the temporary and the permanent dentition. Clinically it is characterised by an opalescent colouring of the teeth, less hardness of the dentin and fractures in the enamel as a consequence of the poor existing dentinal support, which leads to major attrition and the abrasion of the exposed dentin.

DI is classified in three types:

Type I occurs in subjects that suffer OI, being associated with this pathology. Type II is the most common, it is autosomal dominant and is not associated with OI. Type III, also called Brandywine, is the most infrequent, it is autosomal dominant and it only occurs in an isolated area of the State of Maryland, in the United States⁵.

The treatment of OI is palliative and has the purpose of promoting the normal function of the individual.

Physical therapy improves muscle strength and resistance.

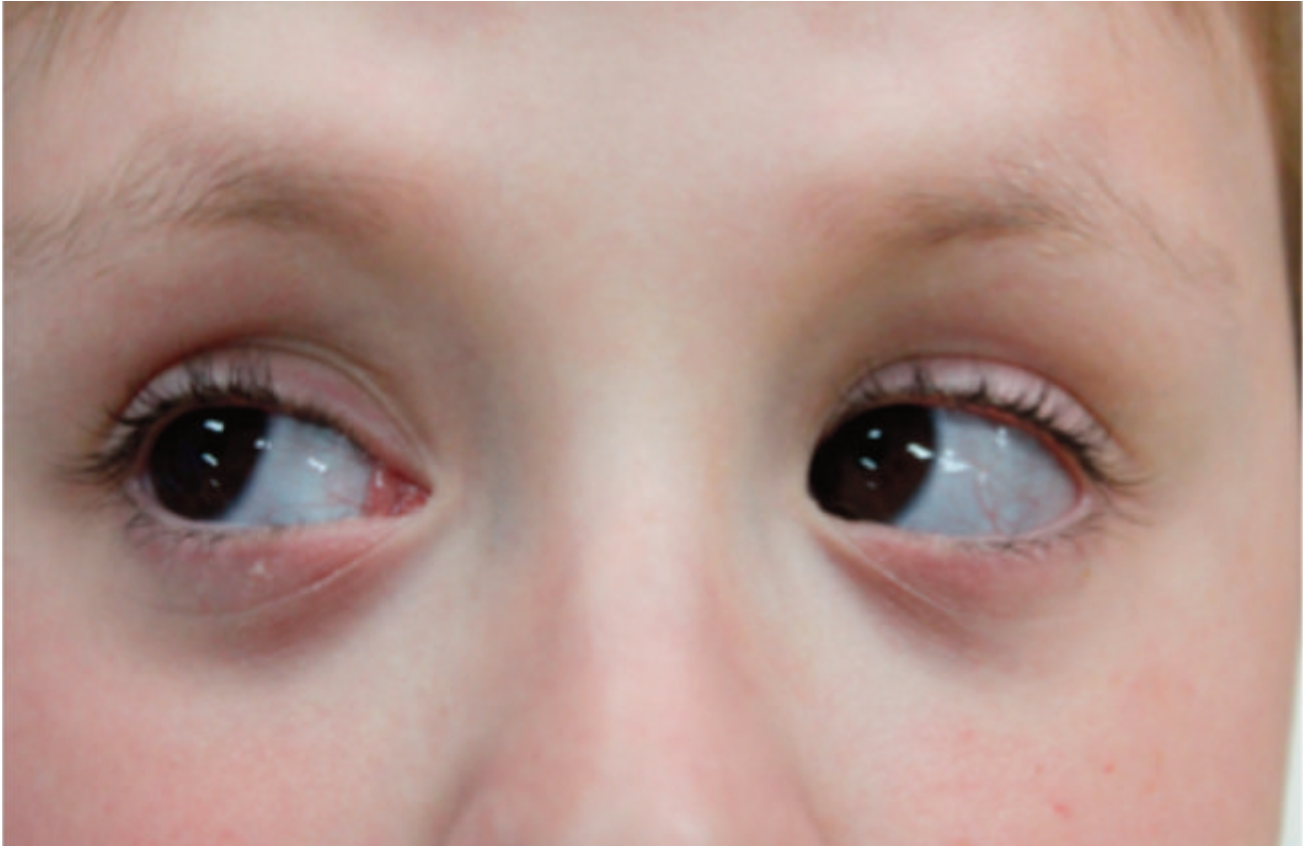

Figure 1. Image of the blue sclera.

Surgery is used to correct or reduce the deformities and to stabilise the fractures of the long bones or the spine.

Odontological interventions are based on the prevention of caries and periodontal disease, as well as on the correction of dental defects and occlusion. It is common to find patients with facial alterations, malocclusions and incorrect maxilomandibular positions, such as maxillary retrognathism and mandibular prognathism. The solution of these disorders is based on the combination of orthodontics with orthognathic surgery, whose results are successful in the majority of the cases, although it is not performed frequently.

The medical treatment is based on the use of calcitonin, sodium fluoride, growth hormone, cortisone, anabolic steroids, vitamins C and D, minerals and bis-

phosphonates. These have turned out to be the most effective medical treatment.

The bisphosphonates minimise the osteoclastic activity and contribute to reduce the pain, to improve the sensation of well-being of the subjects and to increase the mineral bone mass in the vertebrae. The patients must be controlled rigorously due to the possibility of developing osteonecrosis of the maxillae associated with bisphosphonates, although, in the case of children, currently there are not sufficient data that can demonstrate the relation between the treatment with bisphosphonates and the appearance of osteonecrosis.

In paediatric patients it is typical to observe a series of radiological manifestations as a consequence of the treatment with bisphosphonates. The diaphyses of the bones are narrow, however, due to the effect

of the bisphosphonates on the remodelled bone, the metaphyses are thick, and horizontal white lines appear associated with the administration of the drug, with regular spaces that correspond to the intervals between the treatment cycles, demonstrating the existence of bone growth during the therapy^{6,7}.

Currently, new treatments are being developed, such as the bone marrow transplant to increase the osteoblastic activity and genetic therapy^{1,8}.

The objective of the study was to evaluate the presence of fractures and bones affected, the presence of DI, the treatment of the OI and the type of bisphosphonate administered.

MATERIALS AND METHOD

The study began with a sample of 187 patients, which were compiled from the clinical records of the university's own degree "Integrated odontological assistance in children with special needs," of the Stomatology Department IV of the School of Dentistry of the Complutense University of Madrid.

Clinical records were evaluated according to the criteria of inclusion and exclusion, in such a way that of the 187 initial patients, the study was finally conducted for a sample of 17 patients.

Criteria for inclusion:

- patients under 18 years of age
- patients with OI
- patients with presence or absence of DI

Criteria for exclusion:

- Incomplete clinical records
- Patients that did not sign the informed consent form
- Patients with a systemic pathology other than OI

RESULTS

Of the 187 patients of the university's own degree, 17 suffer OI. Regarding them, the following were evaluated through the clinical records:

- Presence of fractures and affected bones
- Presence of DI
- Treatment of the OI
- Type of bisphosphonate administered, in case of receiving this treatment

Of the patients 81% had some type of fracture during their lives. while 19% of the cases did not reflect in the clinical records the history of fractures of the patient.

The bones affected by the fractures, in decreasing order, were the femur in 24% of the cases, followed by the ulna and radius, fingers and the cranium (6% each). Twenty-four percent of the patients suffered multiple fractures and 35% of the cases did not specify the affected bone (Figure 2).

The presence of DI in the patients appeared in 53% of the cases.

In 71% of the cases the patients were treated with bisphosphonates, alone or in combination with calcium, vitamins, calcium and vitamins or vitamins and growth hormone. In 29% of the cases the treatment that the patient receives was not reflected (Figure 3).

The type of bisphosphonate administered was pamidronate in 83% of the cases, followed by alendronate in 8% of the cases. The type of bisphosphonate was not specified in 8% of the patients.

DISCUSSION

In this study, 71% of the patients are undergoing treatment with bisphosphonates, alone or in combination with other drugs.

The benefit of treating OI with bisphosphonates has been sufficiently demonstrated and it is perfectly accepted^{8,9}.

BONES AFFECTED BY THE FRACTURES

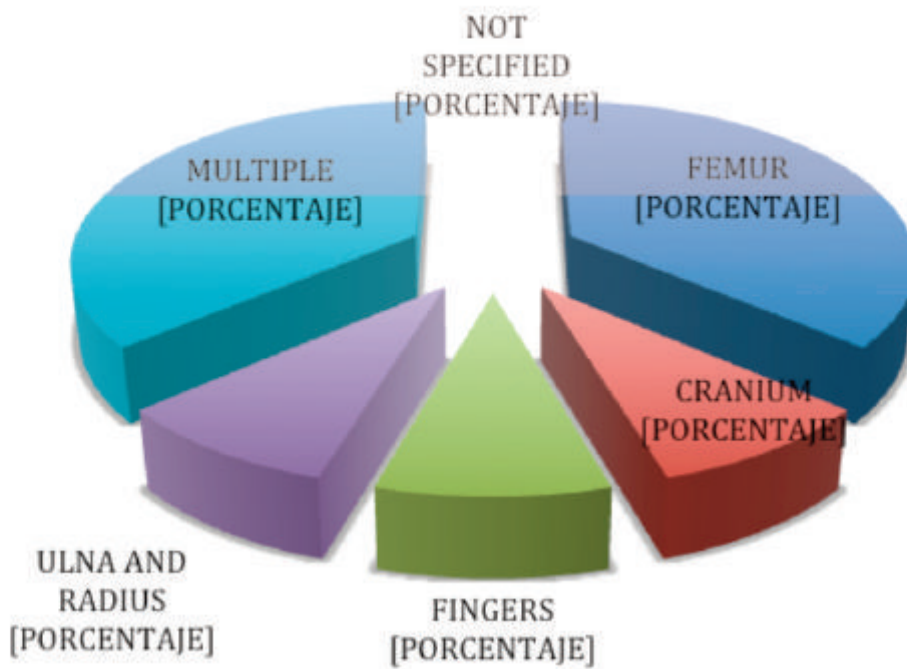


Figure 2. Bones affected by the fractures.

TREATMENT OF OI

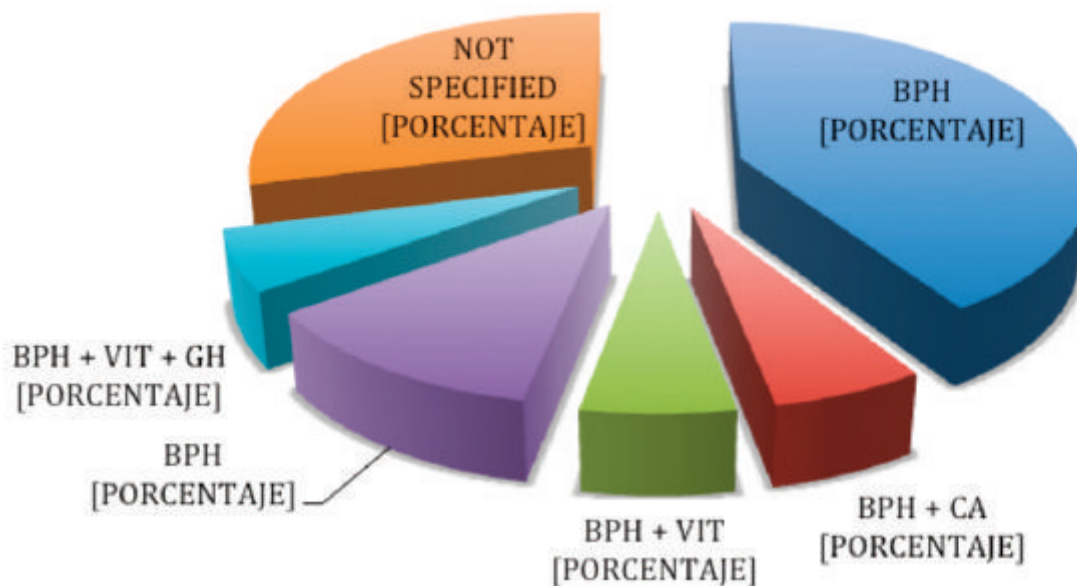


Figure 3. Treatment administered to the patients.

Cases of osteonecrosis of the long bones have been recorded in children with leukaemia and lymphomas, subjected to intense treatment with chemotherapy and cortisone; however, there is no evidence of osteonecrosis of the maxillae associated with bisphosphonates in children with OI^{8,10}.

The pathogenesis of the osteonecrosis due to bisphosphonates is not clear today, but it seems that it is due to a defect in the physiological remodelling of the bone or due to the healing process itself¹¹. On the other hand, bisphosphonates, which are drugs that inhibit the bone resorption, can be classified according to their strength: thus alendronate and risedronate are considered of low strength, pamidronate of medium strength and zoledronate of high strength. While zoledronate and pamidronate are generally used in intravenous form, alendronate and risedronate are principally used in the form of oral medication¹².

In patients studied in this work, 83% received treatment with pamidronate and 8% with alendronate. It has been demonstrated that treatment with pamidronate, alendronate and zoledronate in children with OI subjected to oral surgery does not produce osteonecrosis¹⁰.

Even so, it is necessary to monitor these patients due to the possible action of the cumulative dose of the drug, especially those that are administered parentally⁸.

Maines et al.⁸ proposed the use of neridronate, with a structure similar to alendronate or to pamidronate but less retention time in the body than the other two, and for this reason it contributes to decreasing the risk of developing osteonecrosis.

Malmgren et al.¹⁰ stressed the importance of going to the dentist before and during the OI treatment with bisphosphonates in order to carry out an evaluation of the bucco-dental situation and a subsequent monitoring of the patient.

Eighty-one percent of the patients have suffered, during their lives, some type of fracture, with the fractures of femur and multiple fractures being especially

relevant. On occasions, these could be produced by the effect of the bisphosphonates. The case is recorded of a female of 75 years of age with OI and in treatment with alendronate who suffered an atypical fracture of the femur; however, no case in children was recorded¹³.

The bisphosphonates seem to be effective in the treatment of OI, reducing the annual incidence of fractures, increasing the mineral bone mass in the lumbar vertebrae and hip, as well as avoiding bone resorption and preserving the vertebral morphology^{14,15}.

DI was present in 53% of the patients. Muhney and Campbell¹⁶ affirm that the prevalence of DI is between 8% and 40% in patients with Type I OI, between 43% and 82% in those with Type III OI and between 37% and 100% in patients with Type IV OI.

The odontological handling of the OI patients that have DI, according to the American Academy of Pediatric Dentistry, is based on the prevention of the attrition resulting from the destruction of the enamel and the dentin, the rehabilitation of the dentition, the aesthetic optimisation and the prevention of caries and periodontal disease¹⁷. It is important to consider the existence of calcifications in the root canals when performing endodontic treatments¹⁸ and the possibility of producing mandibular fractures when surgical procedures are performed on these patients¹⁷.

Moderate defects can be treated with adhesive techniques; however, it is preferable to use preformed metallic crowns in temporary dentition when the damage is extensive, and onlays in permanent dentition. These treatments not only rehabilitate the tooth, but they also contribute to stabilising dentition and to avoiding the loss of the vertical dimension. In anterior teeth, the use of different types of aesthetic facets is necessary, but they must be placed in late adolescence, when the complete periodontal maturation has occurred¹⁷.

The conclusions obtained were the following:

1. Of the patients evaluated, 81% present some type of fracture.
2. The bone most affected by the fractures is the femur (24%), along with the multiple fractures.
3. Fifty-three percent of the patients present DI.
4. Seventy-one percent of the patients receive treatment with bisphosphonates, alone or in combination with other drugs.
5. The type of bisphosphonate administered in 83% of the cases is pamidronate.



BIBLIOGRAPHY

1. Rosén A, Modig M, Larson O. Orthognathic bimaxillary surgery in two patients with osteogenesis imperfecta and a review of the literature. *Int J Oral Maxillofac Surg* 2011; 40(8): 866-73.
2. Glorieux FH. Experience with bisphosphonates in osteogenesis imperfecta. *Pediatrics* 2007; Suppl 2: 163-5.
3. Sillence DO, Senn A, Danks DM. Genetic heterogeneity in osteogenesis imperfecta. *J Med Genet* 1979; 16(2): 101-16.
4. Glorieux FH, Rauch F, Plotkin H, Ward L, Travers R, Roughley P et al. Type V osteogenesis imperfecta: a new form of brittle bone disease. *J Bone Miner Res* 2000; 15(9): 1650-8.
5. Rios D, Vieira AL, Tenuta LM, Machado MA. Osteogenesis imperfecta and dentinogenesis imperfecta: associated disorders. *Quintessence Int.* 2005; 36(9): 695-701.
6. Cundy T. Recent advances in osteogenesis imperfecta. *Calcif Tissue Int* 2012; 90(6): 439-49.
7. Glorieux FH, Bishop NJ, Plotkin H, Chabot G, Lanoue G, Travers R. Cyclic administration of pamidronate in children with severe osteogenesis imperfecta. *N Engl J Med* 1998; 339(14): 947-52.
8. Maines E, Monti E, Doro F, Morandi G, Cavarzere P, Antoniazzi F. Children and adolescents treated with neridronate for osteogenesis imperfecta show no evidence of any osteonecrosis of the jaw. *J Bone Miner Metab* 2012; 30(4): 434-8.
9. Nicolaou N, Agrawal Y, Padman M, Fernandes JA, Bell MJ. Maines E et al. Changing pattern of femoral fractures in osteogenesis imperfecta with prolonged use of bisphosphonates. *J Child Orthop* 2012; 6(1): 21-7.
10. Malmgren B, Aström E, Söderhäll S. No osteonecrosis in jaws of young patients with osteogenesis imperfecta treated with bisphosphonates. *J Oral Pathol Med* 2008; 37(4): 196-200.
11. Favia G, Piatelli A, Sportelli P, Capodiferro S, Lezzi G. Osteonecrosis of the posterior mandible after implant insertion: a clinical and histological case report. *Clin Implant Dent Relat Res* 2011; 13 (1): 58-63.
12. Alons K, Kuijpers SCC, de Jong E, van Merkesteyn JPR. Treating low- and medium- potency bisphosphonate-related osteonecrosis of the Jaws with a protocol for the treatment of chronic suppurative osteomyelitis: report of 7 cases. *Oral Surg Oral Med Oral Pathol Oral Radiol Endod* 2009; 107 (2): 1-7.
13. Meier RP, Ing Lorenzini K, Uebelhart B, Stern R, Peter RE, Rizzoli R. Atypical femoral fracture following bisphosphonate treatment in a woman with osteogenesis imperfecta--a case report. *Acta Orthop* 2012; 83(5): 548-50.
14. Li M, Xia WB, Xing XP, Yu W, Hu YY, Jiang Y et al. Benefit of infusions with ibandronate treatment in children with osteogenesis imperfecta. *Chin Med J (Engl)* 2011;124(19): 3049-53.
15. Aström E, Söderhäll S. Beneficial effect of long term intravenous bisphosphonate treatment of osteogenesis imperfecta. *Arch Dis Child* 2002; 86(5): 356-64.
16. Muhney K, Campbell PR. Pediatric dental management of a patient with osteogenesis imperfecta and dentinogenesis imperfecta. *Spec Care Dentist* 2007; 27(6): 240-5.
17. Opsahl Vital S, Gaucher C, Bardet C, Rowe PS, George A, Linglart A, Chaussain C. Tooth dentin defects reflect genetic disorders affecting bone mineralization. *Bone* 2012; 50(4): 989-97.
18. Sanches K, de Queiroz AM, de Freitas AC, Serrano KV. Clinical features, dental findings and dental care management in osteogenesis imperfecta. *J Clin Pediatr Dent* 2005; 30(1): 77-82.